



Vascular surgery for chronic migraine

Elliot Shevel

*The Headache Clinic,
Suite 243, Private Bag
X2600, Houghton 2041,
South Africa
Tel.: +27 114 840 933;
Fax: +27 114 824 167;
E-mail: drshevel@headclin.com*

Background: The superficial branches of the external carotid artery have been shown to be the origin of headache pain in some individuals. Surgical ligation of the temporal artery was first described by Al Zahrawi. Since then, excellent results have been achieved surgically in those patients in whom the superficial vessels have been positively identified as the source of the headache pain. **Aim:** To determine the improvement in quality of life in patients suffering from chronic daily headache (CDH) following cauterization of superficial scalp vessels. **Patients & methods:** In total, 65 patients with CDH, in whom the superficial scalp vessels were positively identified as the source of pain, underwent surgical cauterization of the relevant vessels. **Results:** The quality of life of CDH sufferers in whom the pain was shown to originate in the superficial scalp vessels was significantly improved following surgical cauterization of the relevant vessels. **Conclusion:** Surgical cauterization of superficial scalp vessels can be a valuable treatment modality in selected patients with CDH.

The extracranial branches of the external carotid artery are an important source of pain in some patients with primary headaches [1–16]. In these patients, surgical cauterization of the relevant arteries provides permanent pain relief [17–26]. Chronic daily headache (CDH) refers to headaches that occur for 15 or more days per month. Chronic migraine (CM) is a form of CDH in which patients develop a pattern of daily or near-daily headaches that have features of both migraine and tension-type headache. Most patients with this disorder are women with a past history of episodic migraine without aura, whose attacks have become more frequent over the years. The associated symptoms of photophobia, phonophobia, nausea and vomiting, frequently become less severe and less common [27–30].

In this study, the quality of life (QOL) of patients with CM was measured before surgical cauterization of superficial scalp vessels, and again 1 year later. The purpose was to ascertain the effect of this form of treatment on the QOL of people suffering from CM and in whom the superficial scalp vessels were positively identified as the source of pain by a compression maneuver.

Keywords: chronic migraine, external carotid artery, scalp arteries, surgical cauterization

Patients & methods

Patient selection

In total, 13 male and 52 female patients diagnosed with CM (previously transformed migraine) according to the Silberstein/Lipton

revised criteria [31], and in whom there was a positive diagnosis of extracranial arterial pain, were included in the study. The subjects were recruited from patients attending The Headache Clinic in Johannesburg, South Africa, in whom rescue medication was not effective, and who had not benefited from prophylactic medication. Patients were excluded from the study if they had any clinically significant illness or if they were unfit for general anesthesia. Study procedures were explained to prospective cohorts and their informed consent was obtained.

Diagnosis

To ascertain whether the pain originates in the extracranial vessels, it is necessary to examine the patient while the pain is present. A positive diagnosis is made if the pain diminishes when blood flow to the painful area is interrupted by digital compression of the relevant vessels. When the pressure is removed, the pain returns, usually within a few seconds. The vessels most frequently associated with the pain are:

- The main trunk of the superficial temporal artery
- The frontal branch of the superficial temporal artery
- The occipital artery
- The posterior auricular artery

In most patients, multiple vessels are involved in the pain process and must be cauterized (Table 1).

future
medicine part of fsg

Table 1. Arteries cauterized.

Patient	L ST	L FR	L PA	L OCC	R ST	R FR	R PA	R OCC
1	*	*	*	*	*			
2	*	*	*	*	*	*	*	*
3	*	*	*	*	*	*	*	*
4	*	*						
5	*	*	*		*	*	*	
6	*	*		*	*	*		*
7	*	*	*	*	*	*	*	*
8	*	*	*		*	*	*	
9	*	*	*	*	*	*	*	*
10	*			*	*			*
11	*	*	*	*	*	*	*	*
12	*	*	*	*	*	*	*	*
13	*	*	*		*	*	*	
14	*	*	*	*	*	*	*	*
15	*	*		*	*	*		*
16	*	*	*	*	*	*	*	*
17					*	*		*
18	*	*	*		*	*	*	*
19	*	*	*	*	*	*	*	*
20	*	*	*		*	*	*	
21	*	*	*	*	*	*	*	*
22	*				*	*	*	*
23	*	*		*	*	*		*
24	*				*			
25	*				*			
26	*	*			*	*		
27	*	*	*	*	*	*	*	*
28	*			*	*			*
29	*	*						
30	*				*			
31	*	*			*	*		
32	*	*	*	*	*	*	*	*
33	*	*	*	*	*	*	*	*
34	*	*			*	*		
35	*	*			*	*		
36	*	*		*	*	*		*
37	*	*	*	*	*			*
38	*			*	*			*
39	*	*		*	*	*		*
40	*							
41	*	*	*	*	*			
42	*				*	*		
43	*	*	*		*			

L FR: Frontal branch of the left superficial temporal; L OCC: Left occipital; L PA: Left posterior auricular; L ST: Left superficial temporal; R FR: Frontal branch of the right superficial temporal; R OCC: Right occipital; R PA: Right posterior auricular; R ST: Right superficial temporal.

Table 1. Arteries cauterized (cont.).

Patient	L ST	L FR	L PA	L OCC	R ST	R FR	R PA	R OCC
44	*	*	*	*	*	*	*	*
45	*	*	*		*		*	
46	*	*			*	*		
47	*	*	*	*	*	*		
48	*	*		*	*	*		*
49	*	*	*	*	*	*		
50		*				*		
51	*	*			*	*		
52	*				*			
53	*	*	*	*	*	*	*	*

L FR: Frontal branch of the left superficial temporal; L OCC: Left occipital; L PA: Left posterior auricular; L ST: Left superficial temporal; R FR: Frontal branch of the right superficial temporal; R OCC: Right occipital; R PA: Right posterior auricular; R ST: Right superficial temporal.

Surgical technique

An ultrasonic doppler flow detector model 811-BL (Parks Medical Electronics, Inc.) was used to locate the relevant vessels.

Superficial temporal artery (main trunk)

The main trunk of the superficial temporal artery was approached through a vertical incision just anterior to the pinna, where it crosses superficial to the temporal root of the zygomatic arch. The level at which the main trunk divides into its three terminal branches is not constant. If it divides below the level of the arch, the branches must be cauterized individually.

Superficial temporal artery (frontal branch)

The frontal branch of the superficial temporal artery runs a tortuous course subcutaneously, crossing the temple in an antero-superior direction, and is often visible, particularly during a migraine attack. It was approached via an incision approximately 1 cm long, at right angles to the course of the vessel.

Posterior auricular artery

The posterior auricular artery emerges from the deep tissues in the groove between the cartilage of the ear and the mastoid process, and curves up between the pinna and the skull. It is accessible through a 1-cm incision as it curves round the upper attachment of the pinna. At this level, it is distant from the facial nerve.

Occipital artery

The occipital artery emerges at the level of the superior nuchal line from the deeper tissues of the neck between the attachments of the

trapezius and sternomastoid muscles. It was approached via a horizontal incision approximately 2 cm long.

Quality-of-life test

The results of surgical interventions are best evaluated by measuring improvement in the QOL of the subjects. Randomized, blinded trials cannot be used where surgical procedures are concerned. To do so would mean that half the patients would undergo sham surgery. They would have to undergo operations, with their attendant risks, that consist of merely making the surgical incisions, which would then be sutured. Not only would this be unethical, but there is no possibility that patients with severe daily pain would volunteer for such a trial.

The Migraine Specific Quality of Life Questionnaire (MSQOL) Version 2.1 is a 14-item, self-administered questionnaire that measures three dimensions of QOL [32]. ‘Role function–restriction’ is the percentage of time that the subject can perform normal daily activities. ‘Role function–prevention’ is the percentage productivity while performing normal daily activities. ‘Emotional function’ is the percentage of emotional and relationship ability. All subjects completed the MSQOL questionnaire before surgery, and again 12 months later. The progress of all the subjects was monitored post-surgery and the reduction and/or elimination of pain was immediate. This improvement was maintained until the 12-month MSQOL test, without further interventions. A criticism of the methodology is that it would have been preferable to complete the MSQOL tests every 3 months.

Results

Two out of the 13 male patients and ten out of the 52 female patients were lost to follow-up. As there were no significant statistical differences between the results for males and females, the results for the remaining 11 male and 42 female subjects were combined and the average pre- and post-treatment scores for each parameter were calculated. In the 53 remaining patients, analysis of the pre- and post-treatment data using the Student's paired t-test demonstrated statistically significant improvement in all three parameters. Role function–restriction improved from 35.4 ± 13.2 to $84.7 \pm 17.2\%$ ($p < 0.0001$), role function–prevention improved from 33.7 ± 12.5 to $77.1 \pm 16.4\%$ ($p < 0.0001$) and emotional function improved from 29.1 ± 11.2 to $83.6 \pm 17.5\%$ ($p < 0.0001$) (Figure 1). Two patients in whom the occipital arteries were cauterized had temporary paraesthesia of the skin in the distribution of the left occipital nerve. This resolved in both patients within 6 weeks of surgery.

Discussion

Al Zahrawi (Abu al-Quasim Khalaf bin Abbas Al-Zahrawi) was born in Cordoba in Spain in 936AD. In his treatise, *At-Tasrif*, he described the exposure and division of the temporal artery for the relief of certain types of headache. The next record of this procedure was 500 years later, by Ambroise Pare, one of the great surgeons of the Renaissance, who sectioned his own temporal artery for migraine. Since then, this method

of treating vascular headaches has been reported a number of times [17–26]. Unfortunately, in spite of its low morbidity, this treatment modality is not widely used. A possible reason for this is that nonsurgeons often view even the most minor of surgical procedures, such as this one, as unnecessarily invasive. Others would argue that a one-off minor surgical procedure is less invasive than the long-term use of rescue and prophylactic medication. In the author's experience, most patients prefer the surgical option. In this series, none of the subjects were deriving benefit from medication at the time of surgery.

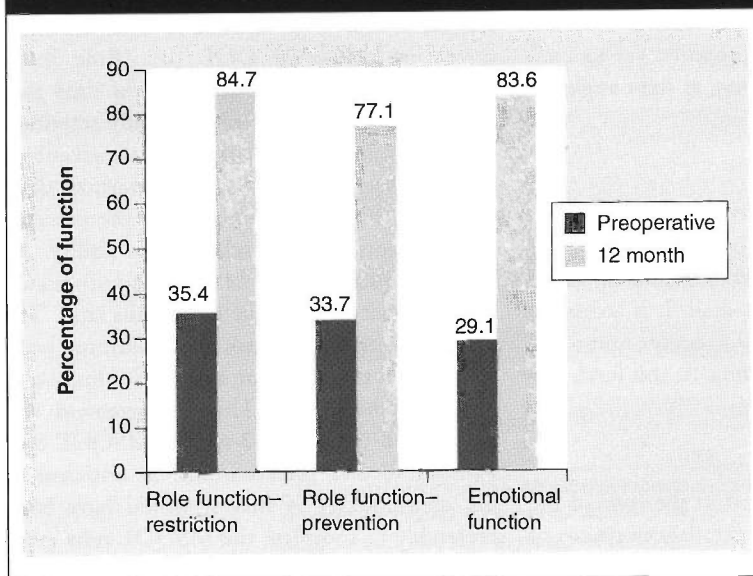
Regional anatomy

The blood supply of the scalp is derived from the superficial temporal, occipital, angular and posterior auricular branches of the external carotid artery, and the supratrochlear and supraorbital branches of the internal carotid artery. An important anatomical feature is that there are extensive anastomoses, both homolateral and heterolateral, between these vessels. These anastomoses are not constant, and vary not only from patient to patient, but at times from left to right in the same patient. Crossing the midline is a communicating vessel between left and right approximately every 5–7 mm [33]. The presence of this anastomotic network complicates the diagnosis, as sometimes the pain improves only when a distant or contralateral vessel is occluded or when a number of vessels are blocked simultaneously. Consequently, each patient has to be carefully assessed to determine exactly which vessels are involved, and only those vessels are ablated.

With regard to the possibility of postoperative morbidity due to insufficient blood supply to the scalp, Abul-Hassan wrote 'It is, of course, well-known that the whole scalp will survive on one superficial temporal artery and vein' [34]. Confirmation of this statement is provided by the results of surgical re-implantation of the traumatically avulsed scalp [35–40]. Experimental confirmation was provided by Marty, who, by measuring transcutaneous oxygen pressure, concluded that one superficial temporal artery can easily ensure the survival of the entire scalp [33].

The classification of CM, as modified by Silberstein and Lipton [32], was used, as it was not possible to use the International Headache Society (IHS) classification. By definition, the IHS classification of CM can only be made if the classification criteria are still fulfilled 2 months after the medication overuse has

Figure 1. Average pre- and 12-month post-surgery scores obtained with the Migraine-Specific Quality of Life Questionnaire Version 2.1.



ceased [41]. As the treatment in this group of patients did not consist of stopping the medication, the IHS criteria could not be applied. The Silberstein/Lipton revised criteria for CM provides three alternative diagnostic links to migraine. The patient must have at least one of the following: a prior history of migraine; a clear period of escalating headache frequency with decreasing severity of migrainous features; or current superimposed attacks of headaches that meet all the IHS criteria for migraine except duration [42].

The intensity of the pain in migraine, and the concomitant neurological, gastrointestinal and sensory symptoms, significantly reduce the QOL of migraineurs [43,44]. The QOL of migraineurs is worse than in conditions such as arthritis and diabetes, and is comparable to the level of dysfunction seen with recent cardiac infarction or

congestive cardiac failure [45]. In this study, the QOL of patients with CM who underwent surgical cauterization of selected arteries was significantly improved 12 months postsurgery.

Conclusion

In selected patients with a severely compromised QOL, and particularly those that do not derive adequate relief from pharmacotherapy, surgical cauterization of positively diagnosed superficial scalp arteries can be a life-changing experience.

Future perspective

Most patients, given the choice between a one-off minor surgical procedure and an indeterminate period of taking prophylactic and/or rescue medication, choose the surgery option. In spite of this, it is unlikely that surgical cauterization of superficial scalp vessels will gain favor among headache specialists for two important reasons. First, the intracranial arteries are widely believed to be the only source of pain in primary headaches with a vascular component, and many prominent experts still doggedly maintain that the extracranial vessels are not involved at all. This is in spite of the fact that the involvement of the intracranial arteries in these conditions has never been substantiated by scientific investigation. Second, most headache specialists are not surgeons. Nonsurgeons often balk at the idea of a surgical option, no matter how minor the intervention.

Executive summary

- Chronic daily headache is a debilitating condition.
- Patients often do not respond to either prophylactic or rescue medication.
- In some of these patients, it can be demonstrated that the pain originates in the superficial scalp arteries.
- Statistical analysis of the results of surgery showed a significant improvement in quality of life.
- Surgical cauterization of the relevant vessels should be considered in selected patients.

Literography

Hmaidan Y, Cianchetti C: Effectiveness of a prolonged compression of scalp arteries on migraine attacks. *J. Neurol.* 253, 811–812 (2006).

Shevel E, Spierings EH: The role of the extra cranial arteries in migraine headache: a review. *Cranio* 22, 132–136 (2004).

Christiansen I, Iversen HK, Olesen J: Headache characteristics during the development of tolerance to nitrates: pathophysiological implications. *Cephalalgia* 20, 437–444 (2002).

Spierings ELH: *Migraine: Questions and Answers*. Merit Publishing International, Coral Springs, FL, USA (1995).

Vijayan N: Head band for migraine headache relief. *Headache* 33, 40–42 (1993).

Jensen K: Extracranial blood flow, pain and tenderness in migraine. Clinical and experimental studies. *Acta Neurol. Scand.* (Suppl.) 147, 1–27 (1993).

7. Iversen HK, Nielsen TH, Olesen J, Tfelt-Hansen P: Arterial responses during migraine headache. *Lancet* 336, 837–839 (1990).

8. Drummond PD: Scalp tenderness and sensitivity to pain in migraine and tension headache. *Headache* 27, 45–50 (1987).

9. Lipton SA: Prevention of classic migraine headache by digital massage of the superficial temporal arteries. *Ann. Neurol.* 19, 515–516 (1986).

10. Drummond PD, Lance JW: Facial temperature in migraine, tension-vascular, and tension headache. *Cephalalgia* 4, 149–158 (1984).

11. Drummond PD, Lance JW: Extracranial vascular changes and the source of pain in migraine headache. *Ann. Neurol.* 13, 32–37 (1983).

12. Knapp TW: Treating migraine by training in temporal artery vasoconstriction and/or cognitive behavioral coping: a one-year follow-up. *J. Psychosom. Res.* 26, 551–557 (1982).

13. Louis S: A bedside test for determining the sub-types of vascular headache. *Headache* 21, 87–88 (1981).

14. Tunis MM, Wolff HG: Studies on headache; long-term observations of the reactivity of the cranial arteries in subjects with vascular headache of the migraine. *Arch. Neurol. Psychiatry* 75, 551 (1953).

15. Wolff HG, Tunis MM: Analysis of cranial artery pressure waves in patients with vascular headaches of the migraine type. *Trans. Assoc. Am. Physicians* 65, 240 (1952).

16. Tunis MM, Wolff HG: Analysis of cranial artery pulse waves in patients with vascular headache of the migraine. *Am. J. Med. Sci.* 224, 565 (1952).

17. Shi FY: Morphological studies of extracranial arteries in patients with migraine. [Chinese] *Zhonghua Bing Li Xue Za Zhi* 18, 271–273 (1989).

18. Hankemeier U: Therapy of pulsating temporal headache. Resection of the superficial temporal artery. [German] *Fortschr. Med.* 103, 822–824 (1985).

RESEARCH ARTICLE – Shevel

19. Rapidis AD: The therapeutic result of excision of the superficial temporal artery in atypical migraine. *J. Maxillofac. Surg.* 4, 182–188 (1976).
20. Holland JT: Three cases of vascular headache treated by surgery. *Proc. Aust. Assoc. Neurol.* 13, 51–54 (1976).
21. Florescu V, Florescu R: Value of resection of the superficial temporal vasculo-nervous bundle in some cases of vascular headache. [Romanian] *Rev. Chir. Oncol. Radiol. ORL Oftalmol. Stomatol. Otorinolaringol.* 20, 113–117 (1975).
22. Bouche J, Freche C, Chaix G, Dervaux JL: Surgery by cryotherapy of the superficial temporal artery in temporo-parietal neuralgia. [French] *Ann. Otolaryngol. Chir. Cervicofac.* 91, 56–59 (1974).
23. Cook N: Cryosurgery of migraine. *Headache* 12, 143–150 (1973).
24. Murillo CA: Resection of the temporal neurovascular bundle for control of migraine headache. *Headache* 8, 112–117 (1968).
25. White JC, Sweet WH: *Pain: Its Mechanisms and Neurosurgical Control*. Charles C Thomas, Springfield, IL, USA (1955).
26. Nadler SB: Paroxysmal temporal headache. *JAMA* 29, 334–335 (1945).
27. Mathew NT, Stubits E, Nigam MP: Transformation of episodic migraine into daily headache: analysis of factors. *Headache* 22, 66–68 (1982).
28. Mathew NT, Reuveni U, Perez F: Transformed or evolutive migraine. *Headache* 27, 102–106 (1987).
29. Mathew NT: Transformed migraine. *Cephalalgia* 13(Suppl. 12), 78–83 (1982).
30. Saper J: *Headache Disorders: Current Concepts in Treatment Strategies*. Wright-PSG, Littleton, MA, USA (1983).
31. Silberstein SD, Lipton RB, Sliwinski M: Classification of daily and near-daily headaches: field trial of revised IHS criteria. *Neurology* 47, 871–875 (1996).
32. Patrick DL, Hurst BC, Hughes J: Further development and testing of the migraine-specific quality of life (MSQOL) measure. *Headache* 40(7), 550–560 (2000).
33. Marty F, Montandon d, Gumener R, Zbrodowski A: Subcutaneous tissue in the scalp: anatomical, physiological, and clinical study. *Ann. Plast. Surg.* 16, 368–376 (1986).
34. Abul-Hassan HS, von Drasek Ascher G, Acland RD: Surgical anatomy and blood supply of the fascial layers of the temporal region. *Plast. Reconstr. Surg.* 77, 17–24 (1986).
35. Garti JE, LaRossa D: Scalp avulsions and review of successful reimplantation. *Ann. Plast. Surg.* 6, 127 (1981).
36. McCann J, O'Donoghue J, Kaf-al Ghazal S, Johnston S, Khan K: Microvascular replantation of a completely avulsed scalp. *Microsurgery* 15, 639–642 (1994).
37. Eren S, Hess J, Larkin GC: Total scalp replantation based on one artery and one vein. *Microsurgery* 14, 266–271 (1993).
38. Kaplan HY, Yaffe B, Borenstein A: Single artery replantation of totally avulsed scalp. *Injury* 24, 488–490 (1993).
39. Borenstein A, Yaffe B, Seidman DS, Tsur H: Microsurgical replantation of two totally avulsed scalps. *Isr. J. Med. Sci.* 26, 442–445 (1990).
40. Nahai F, Hurteau J, Vascones LO: Reimplantation of an entire scalp and ear by microvascular anastomosis of only one artery and one vein. *Br. J. Plast. Surg.* 31, 339 (1978).
41. Headache Classification Committee of the International Headache Society: The International Classification of Headache Disorders (2nd Edition). *Cephalalgia* 24(Suppl. 1), 32 (2004).
42. Silberstein SD: *Chronic Daily Headache*. Proceedings of the Chronic Daily Headache International Study Group, Department of Neuroscience, University of Perugia, Italy (2003).
43. Dahlof CG, Solomon GD: The burden of migraine to the individual sufferer: a review. *Eur. J. Neurol.* 5, 525–533 (1998).
44. Osterhaus JT, Townsend RJ, Gandek B, Ware JE Jr: Measuring the functional status and well-being of patients with migraine headache. *Headache* 34, 337–343 (1994).
45. Solomon GD, Skobieranda FG, Gragg LA: Does quality of life differ among headache diagnoses? Analysis using the medical outcomes study instrument. *Headache* 34, 143–147 (1994).